

# Functional Field of Vision

Lea Hyvärinen  
Lea-Test Ltd, Apollonkatu 6 A 4, FIN-00100 Helsinki

The size and the quality of visual field are important basic functions to be assessed as a part of functional vision assessment.

Evaluation of functional field losses can be organized as follows:

## **1. Major field losses:**

- A. *Field losses due to pathway damage*
  - half field loss, right, left
    - remaining motion perception in 'blind' field half
  - quadrant losses
- B. *Field losses due to disorders of the eyes*
  - ROP
  - Congenital Glaucoma
  - Coloboma
  - Retinitis Pigmentosa and related disorders
- C. *Central Scotoma*

## **2. Minor field losses**

## **3. Distortion of the image**

## **4. Perceptual losses without measurable field loss**

## **5. Restriction of functional visual field due to motor problems**

It may be wise to clarify some definitions:

*Anterior visual pathways* contain eyes and the pathway up to the lateral geniculate nucleus (LGN), and *posterior visual pathways* contain the nerve fibres from the LGN to the primary visual cortex. *Anterior visual impairment* is due to damage to anterior pathways. *Posterior visual impairment* is due to damage to posterior visual pathways but may also be due to abnormal function in higher visual functions in the associative visual cortices without pathway damage.

Information on visual field is given as drawings that depict the loss of function as it is projected onto the physical space around us. However, because central parts of visual field occupy much more cortical area in the primary visual cortex, they are magnified (= cortical magnification) in relation to the peripheral parts of the visual field (as illustrated in Figure 1).

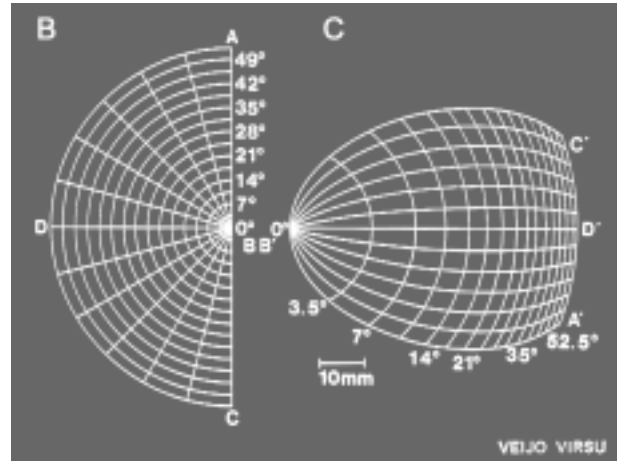


Figure 1. Relationship between the physical environment and its image in the primary visual cortex. A. The main building of the University of Helsinki as a camera and the visual system record it and its representation in the visual cortex. The fixated centre of the picture is located at the most posterior part of the visual cortex and thus at the sides of the picture. B. Visual half space as represented in C. Relative size of the different parts of the visual field of B in the primary visual cortex. The central 12 –13 degrees may occupy one half of all area of the primary visual cortex. (Pictures by Veijo Virsu 1981, reproduced by permission.)

Cortical magnification is the anatomical correlate of the fact that visual information in the more peripheral parts of the visual field is much less visible than in the centre.




Figure 2. If you fixate the STOP-sign at the left lower corner of the picture for a few seconds, the dot in the right upper corner of the picture disappears. If there were another dot flickering, as there is in the PowerPoint presentation, the flickering dot would remain visible and now and then would make also the grey dot visible.

Visual pathways have another basic property that is good to remember: visual information that is not moving loses its representation in a few seconds. This can be demonstrated with a simple picture (Figure 2).

The phenomenon described in Figure 2 is important in the assessment of scotomas: Areas of visual field where nothing is happening, disappear from consciousness. Each of us has a blind spot - the area corresponding to the nerve head - yet we cannot subjectively see it although it can be documented with perimetry. Similarly, scotomas caused by retinal changes are subjectively experienced as losses of information first when they are really large. In the very centre of the visual field the subjective experience of a scotoma varies depending on the structure of the lesion causing it. If there is bleeding into or on the central retina there is a dark shadow in the subjective visual field. If the bleeding is behind the retina the scotoma is a cloudy area in the corresponding area of the visual field. *When we assess the recordings of perimetric investigations we must not take them at face value but ask the person what (s)he subjectively experiences.*

Scotomas caused by damage to the posterior pathways may be only partial because visual information may be transferred via the tectal pathway (Figure 3.) to subcortical and cortical visual areas and the damage may be limited to higher-order cortical areas. In this pathway magnocellular information dominates and thus movement perception may be present even if form perception is lost. Movement perception is not assessed as a part of clinical examinations. Also assessment of colour perception is often forgotten. Thus, in the clinical examinations only one, form perception, of the three functions of the visual system is measured. *We see forms, colours and motion and all three need to be assessed in the functional assessment.*

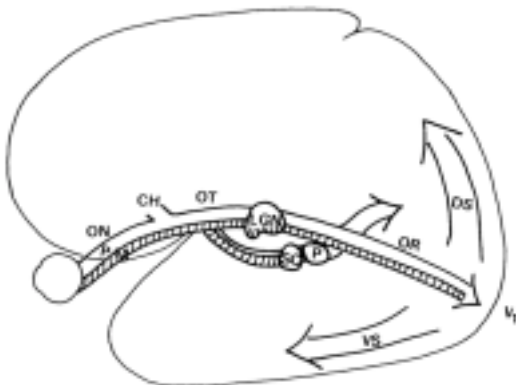


Figure 3. Visual pathways transfer information via the retinocalcarine pathway from the eyes via the LGN to the primary visual cortex and via the tectal pathway bypassing the LGN via superior colliculus (SC) and pulvinar (P) to cortical visual functions. Parvocellular information dominates the retinocalcarine pathway and magnocellular information the tectal pathway. Parvocellular fibres transfer all colour information and high contrast black-&-white information, magnocellular fibres transfer all movement related information and low contrast black-&-white information.

There is one more physiologic function that we need to be aware of when assessing functional visual field: short term memory. Since the eyes move, the area of scotoma falls on different objects in the environment and visual information from the nearby sighted areas fills in the area of the scotoma and thus a small scotoma does not have any functional importance. Even large scotomas are effectively filled in by visual information stored in the short time memory.

After this introduction you might be convinced that it is not possible to reliably assess visual fields. It is quite true but we can learn enough to guide ourselves in the selection of learning techniques. Clinical findings give us a starting point from where to go on with a more detailed analysis. A few examples may demonstrate what to look for:

# 1. Major losses of visual field

## A. Field losses due to pathway damage

Loss of one half of the visual field may be on the left or right side (=hemianopia) or involve the lower part of the visual field, more rarely the upper part. Each type of loss affects both orientation in space and near vision tasks, especially reading if there is no macular sparing, sparing of the central 10-12 degrees of the affected side (Figure 4.)

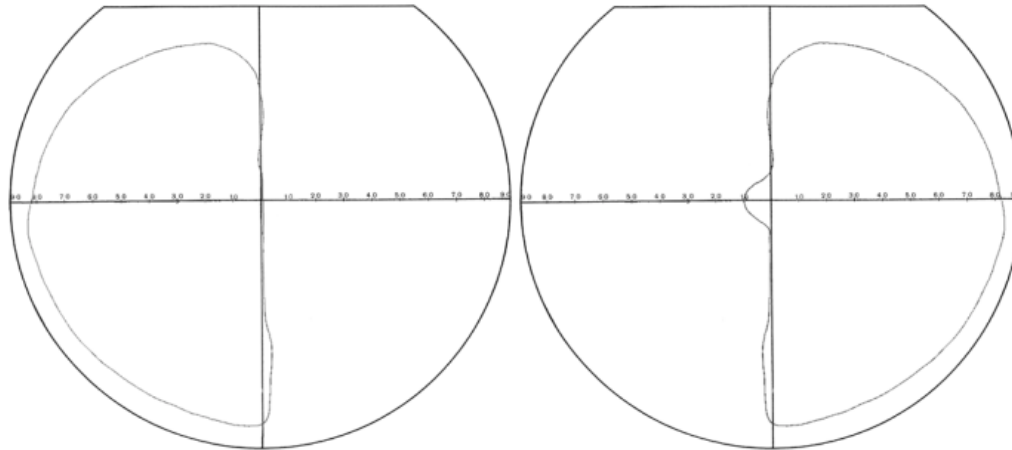


Figure 4. In hemianopia there may be total loss of the macular function (A) or the macular fibres are spared and thus the important central 10-12 degrees of the visual field are functioning (B).

If there is no macular sparing, hemianopia requires specific training in orientation and mobility to teach the child to regularly look over to the non-functioning side. Some children with the lesion in the posterior part of the optic radiation may have quite good function in their 'blind' hemifield although the usual perimetric findings give the impression that there is no function. As an example is a person (Case 1), who had left sided hemianopia (Figure 5.B) but had normal flicker sensitivity in the hemianopic field. If fingers were moved in his 'blind' hemifield he reported seeing the movement but not any forms at 25 degrees from the centre of the visual field.

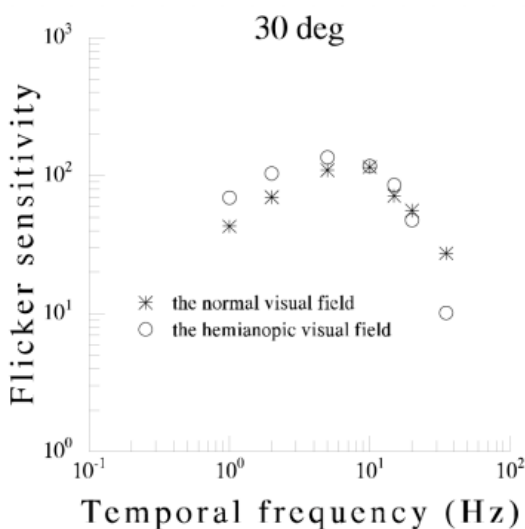


Figure 5. Left sided hemianopia with macular sparing to nearly 10 degrees from the centre of the field (Figure 4 B). Flicker sensitivity measurements at 30 degrees' eccentricity show symmetric findings in the normal and in the 'blind' hemifield. Subjective experience of the environment on the left is different from that on the right, it is 'lighter' and objects are visible but without distinct form to about 60 degrees instead of the normal 90 degrees. In this case there was no difficulty in orientation probably due to normal motion perception (= perception of movements).

We learn to use information for orientation in environment only if we are responsible for directional decisions and actively move. Next example, Case 2, is a boy who got his electric wheel chair and was found not to know how to find his way from the school to his home. He had been pushed in a

wheel chair until he got the electric wheel chair. We recorded him driving his wheel chair from the school to his home and used the video in mental training through visualisation (Hyvärinen 2001). After having watched the video numerous times he memorised the route and has later been able to train independent travelling in a larger area around his home. His field defect covered nearly the entire left lower quadrant, which often is combined with cortical lesions in the area responsible for spatial awareness and planning.

If the visual field loss is in the lower part of the field it effectively disturbs mobility. The child walks with his/her head bent down to compensate for the field loss. Some children get much better posture when using strong prism glasses.

The effects on reading depend on the size of macular sparing. If there is no macular sparing a right-sided field loss makes planning of saccades to land on the next word inadequate; it is not possible to make motor plans for the saccadic movement without proper visual map.

Case 3: A child with right-sided loss of visual field had tilted head posture when reading. When he was taught to hold the book tilted to gain more space for the saccades his head posture became normal. – Another child preferred holding the book upside down and reading from right to left.

Case 4. A child with left sided visual field loss in the centre of the visual field had difficulties in performing the long saccade from the end of a line to the beginning of the next line. A card held below the line to be read was moved one line at a time and helped in finding the beginning of the next line.

Although hemianopic reading difficulties are usually due to pathway damage, also retinal lesions causing loss of visual field immediately to the right or left of fixation result in similar reading problems.

### *B. Field losses due to disorders of the eyes*

The most common causes of visual field defects in children are retinopathy of prematurity (ROP), congenital glaucoma, coloboma and retinitis pigmentosa.

ROP and congenital glaucoma usually lead to constriction of the visual field. There may be one or several large scotomas inside the visual field and the sensitivity of the whole field is often reduced. These changes cause difficulties in orientation and mobility due to poor visibility of landmarks and greater than usual need of magnification of texts.

Coloboma means developmental closure defect in the lower part of the eye leading to lack of retina and/or lower part of the iris. Since there is no retina in the lower part of the eye the corresponding part of the upper visual field is missing. The lesion may involve one or both eyes. Even when it is in both eyes the blind areas are seldom symmetric. If the child uses both eyes the field defects may overlap each other only minimally.

Retinitis pigmentosa has several clinical variants with different speed in the development of visual field defects. The most common type of vision loss starts in the 'midperiphery', i.e. not in the middle or in the periphery but around the central visual field (Figure 6.) This area corresponds to the area of greatest concentration of rod cells in the retina. First there are small patches of loss of function. By and by these patches enlarge and form a partial, later a complete ring around the

central visual field. Although this so called ring scotoma may not show any responses even to the largest, brightest stimulus of Goldman perimetry there may be perception of flicker and movement. Therefore children with ‘absolute’ ring scotoma may not have difficulties in mobility.

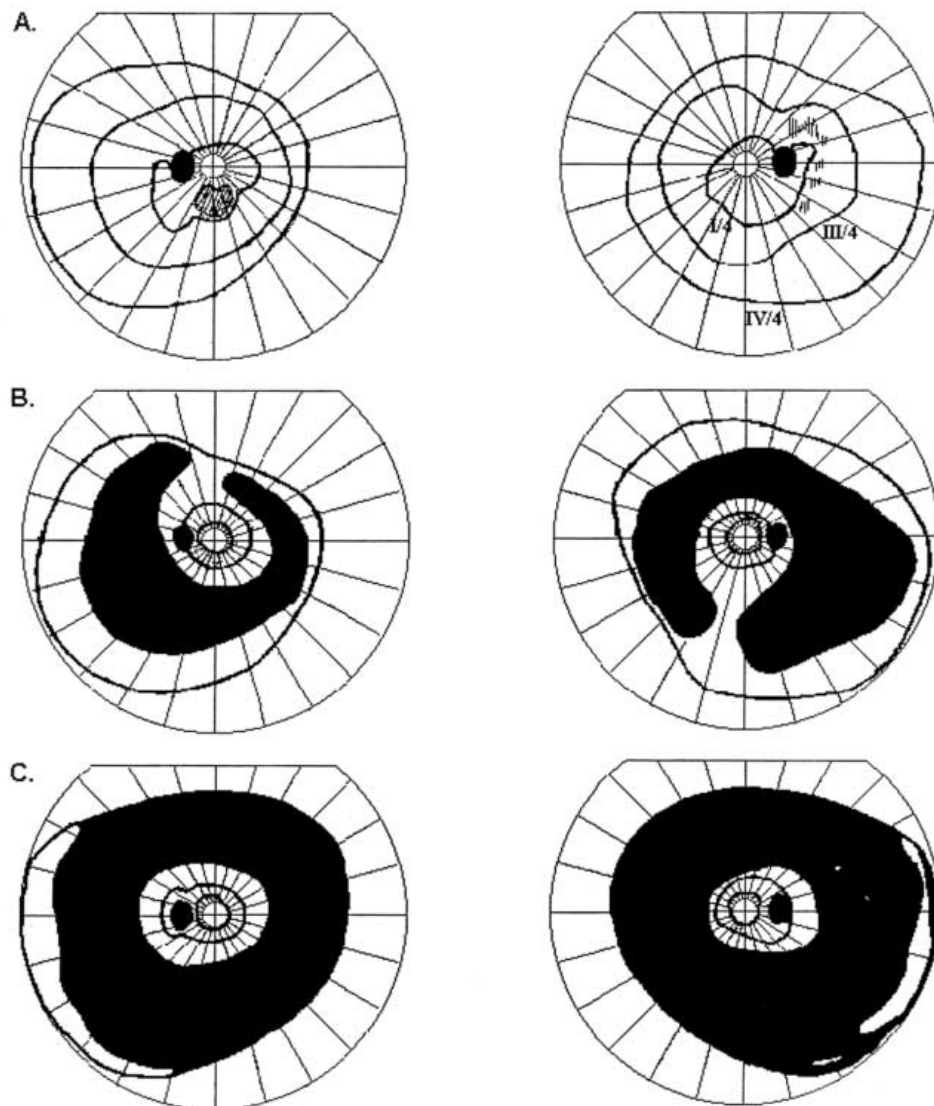


Figure 6. Development of visual field changes in typical cases of retinitis pigmentosa. A. Small patches of relative loss of function in midperiphery. B. The patches become confluent and form a ring scotoma around the central visual field. C. The ring scotoma becomes larger and only small remnants of the peripheral visual field remain. These pictures are recordings of Goldman perimetry, which does not record perception of movement. Although the scotomatous areas are painted black, it does NOT mean total loss of vision.

In the assessment of visual field in retinitis pigmentosa, automated perimetry often results in even more misleading findings than Goldman perimetry. When vision for orientation and mobility is assessed, children with RP and related disorders must be observed in different game, play and orientation situations if motion perception cannot be investigated.

### C. Central Scotoma

Central scotomas usually damage the very centre of the visual field; rarely there is a minute area of function within the scotoma. The child usually learns to use an area with best image quality and thus has extrafoveal fixation at this preferred retinal locus (PRL). If the locus with best resolution is small the child may use another retinal area with lower visual acuity in tasks that require larger area of viewing. In the assessment of reading field it is of interest to know whether the child uses several fixation areas. This can be done by mapping the location of the blind spot while the child fixates on texts of different sizes in the middle of the Extrafoveal Fixation Recorder (Figure 7).

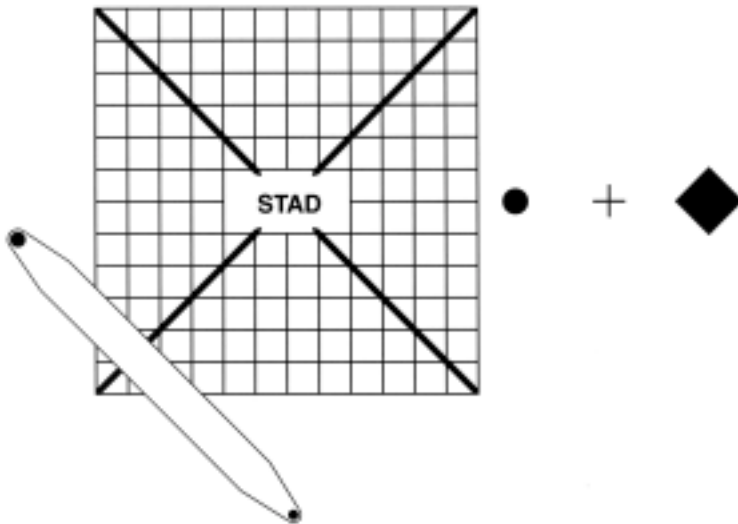


Figure 7. Extrafoveal Fixation Recorder is a derivate of the well-known Amsler chart. There is a hole in the middle of the chart where to place the different fixation targets, usually texts of different sizes.

By plotting the location of the blind spot it is possible to detect whether the fixation moves from one retinal area to another: the location of the blind spot shifts as much as does the area used for fixation.

In searching for the blind spot the small pointer with a dot at both ends is used as the stimulus. The three markings on the right of the chart, dot, cross and diamond, fall within the blind spot at different distances when a person with normal central visual field fixates the centre of the chart and do not disappear at any distance if the blind spot has shifted from its normal place.

## 2. Minor field losses

Small lesions in the retina may cause minor visual field defects when there is a larger lesion in the other visual field so that it cannot compensate for the small field defect. The most common cause, however, is loss of a small group of nerve fibres in the optic radiation. In both types of lesions the small area of the primary visual cortex that is devoid of information is taken over by visual information coming via the surrounding nerve fibres. Functionally the scotoma disappears and affects function only when a minute detail falls on it. Reading is a typical task disturbed by minute field defects on the right of the fixation area.

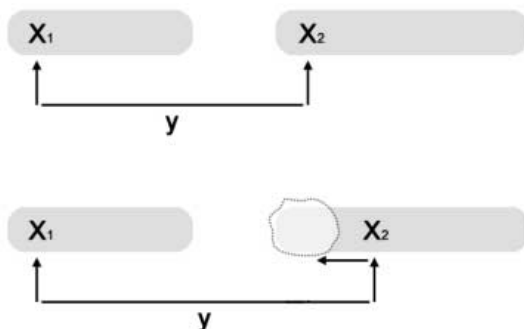


Figure 8. Simplified diagram of reading two words. When a beginning reader fixates his/her gaze on the beginning of a word and reads it, preattentive visual functions simultaneously 'measure' the distance 'y' to the next fixation (if the child reads letter by letter, this distance changes several times). The visual map is used by motor planning units that give the command to the motor units to execute a proper movement. Before the movement can occur, another command to detach from the present fixation is given. After that the saccade moves the gaze to the next fixation area where attention is fixed onto the beginning of the word. Problems in reading may be caused by inadequacies in any of these functions: fixation, reading, visual preattentive planning, motor planning or motor execution. If there is scotoma covering the beginning of the

next word (due to a minute lesion in the retina or the optic nerve), visual information for motor planning is misleading. If the scotoma is due to a posterior lesion, there is no scotoma in the image that reaches the tectal pathway and thus information for motor planning is correct. - Scotoma falling in the middle of a word makes one or two letters disappear.

Case 5: A child had atypical reading difficulty, errors in spelling occurred without any typical linguistic pattern. Visual acuity and contrast sensitivity were at low normal values with lightly increased crowding phenomenon. The child had very mild motor problems and was known to have mild periventricular leucomalacia. Therefore small visual field losses were searched by asking her to read *texts of different sizes*. The results were following:

8-point text:.... usually he was given > she read: usually was given

12 point text: ... what amount is > she read: what mount is

18 point text: ... **main reason** > she read: man reason ('reason' was read slowly)

When the text size was 28 points reading errors disappeared. The errors were losses of letters at a certain distance from the fixation of the previous or the same word. The likely cause is a small scotoma that "eats" one or two letters depending on the text size.

Since small visual field defects are common in children with even mild forms of periventricular leucomalacia, reading should be taught and tested using different text sizes to become aware of the quality of the reading field of the child.

### **3. Distortion of the image**

Distortion of image due to multiple small scotomas or due to folds or stretching of the retina are difficult to diagnose before the child is old enough to use such concepts as 'straight lines', 'perpendicular' and 'smooth curve'. The child is so accustomed to the image quality that (s)he rarely, if ever, spontaneously says anything about what his/her world looks like. Older children learn to understand their vision better when the structure of the image is analysed in detail. This may also lead to use of different magnifications in different tasks to minimise the disturbances in the central visual field.

### **4. Perceptual losses without measurable field loss**

Perceptual losses do not belong to assessment of visual field. They are mentioned here because they sometimes simulate information loss due to a scotoma. A typical situation is loss of recognition of facial features: When a young child who obviously sees minute details and seems to have normal visual functions does not recognize family members and peers, distortion and/or scotomas of central visual field may be suspected. In such a situation testing of recognition of facial features at close distances and using magnifying mirrors may prove that scotomas cannot explain the difficulty because it is unrelated to the image size. Further testing using colour photographs (where, however, the child may use other cues like clothing) and drawings at different contrast levels, the Heidi Expressions etc., may lead to correct diagnosis of a visual agnosia.

### **5. Restriction of functional visual field due to motor problems**

Functional visual field is much larger than the binocular visual field. Because the eyes move and the short term memory combines information from several fixations we are aware of our environment



some 20-30 degrees on both sides behind us. If eye movements are restricted and need to be compensated by head movements, which often are not normal in these children, the functional visual field is smaller than normal.

Spastic children with uncontrolled head and body movements backwards cannot use their visual field during these abnormal movements. Often motor disturbance occurs simultaneously also in the intraocular muscles causing transitory myopia of 10-15 dioptres and thus disappearance of the surrounding space in blur.

## **Summary**

Visually impaired children may have visual field defects of many different kinds. Clinical measurements often give a good start to the functional assessment but should not be taken as a true and complete description of the visual field. For orientation in the environment, mobility and for sustained near vision tasks a detailed functional assessment is necessary.

## **Reference:**

Hyvärinen L (2001) LH-Materials for Teaching, a CD with video sequences on assessment of vision in children with vision problems.